


The DynaNail® TTC Fusion System has proven clinical success in treating high-risk patients with complex pathologies.



Tibiototalcalcaneal Arthrodesis Utilizing a Titanium Intramedullary Nail with an Internal Pseudoelastic Nitinol Compression Element: A Retrospective Case Series of 33 Patients

Surgeon Author(s): Kent Ellington, MD, Samuel Ford, MD (OrthoCarolina Foot & Ankle Institute), John Kwon, MD (Harvard Medical School)

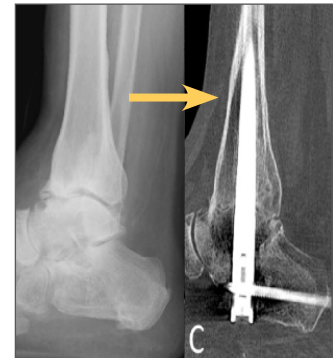Reference: *Journal of Foot & Ankle Surgery* (in press)

"The DynaNail is safe and effective in generating axial compression across both [...] joints, [...] even in the setting of challenging clinical scenarios."

Study Type: Retrospective Case Series

No. of Patients: 33 (30% Diabetic, 24% Charcot, 24% Talar AVN)

- Fusion defined as >50% bony bridging on CT scan
- 90% fusion of all arthrodesis surfaces
- 71% fusion in patients with Charcot neuroarthropathy
- 21% re-operation rate (0% for non-union)



Revision Tibiototalcalcaneal Arthrodesis with a Pseudoelastic Intramedullary Nail – A Case Study

Surgeon Author(s): Dan Latt, MD (University of Arizona)

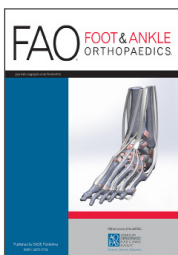
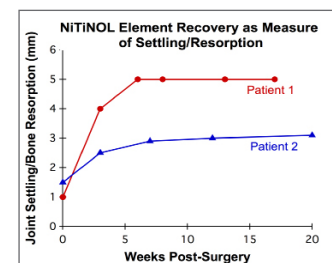
Reference: *Foot & Ankle Specialist*, 2017 Feb; 10 (1): 75-81.

"These cases provide early evidence that sustained compression via an intramedullary nail can lead to rapid successful hindfoot fusion when standard approaches have failed."

Study Type: Case Report

No. of Patients: 2

- Tibiototalcalcaneal arthrodesis revision surgery with the DynaNail
- 2/2 fusion on CT at 3 months post-surgery (both diabetic with Charcot neuroarthropathy)
- At 1+ year follow-up, alignment maintained with no reported issues



Total Ankle Replacement Conversion to Tibiototalcalcaneal Arthrodesis with Bulk Femoral Head Allograft and Pseudoelastic Intramedullary Nail Providing Sustained Joint Compression: A Case Report.

Surgeon Author(s): Mark Conklin, MD (Panorama Orthopedics, Denver, CO)

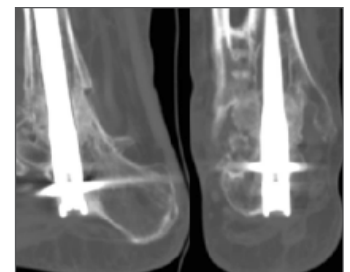
Reference: *Foot & Ankle Orthopaedics*, 2018; (in press)

"The pseudoelastic nail's combined sustained compression and ability to immediately dynamize at time of surgery potentially mean [...] greater load sharing between hardware and bone, which could limit the risk of hardware failure and potentially allow for earlier safe weight bearing."

Study Type: Case Report

No. of Patients: 2

- First report describing successful conversion of failed total ankle replacement to TTCA using the DynaNail and femoral head allograft
- 2/2 patients achieved fusion on CT by 6 months post-surgery
- Time to weight-bearing: 6 weeks
- At two years post-surgery, function restored and both patients satisfied with procedure





Tibiototalcaneal Arthrodesis Using a Nitinol Intramedullary Hindfoot Nail

Surgeon Author(s): Andrew Hsu, MD, Kent Ellington, MD (OrthoCarolina Foot & Ankle Institute), Sam Adams, MD (Duke University)

Reference: *Foot & Ankle Specialist*, 2015; 8(5): 389-96.

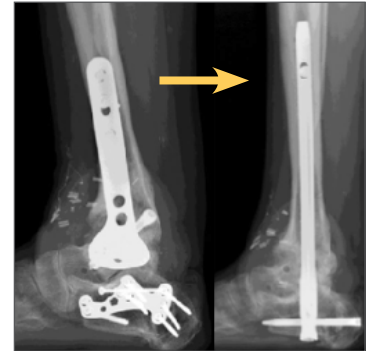
"...we have found that the nail is safe, reliable, and has promising clinical and radiographic results in settings of hindfoot arthritis, complex deformity, Charcot arthropathy, and talar avascular necrosis."

Study Type: Expert Opinion

- Describes design rationale, performance, and surgical technique for the DynaNail
- Demonstrates that the DynaNail maintains compression for over 6 mm of simulated bone resorption compared with another internal compression nail that loses compression after 1 mm

Case Example: Chronic smoker underwent TTCA to revise failed tibiotalar arthrodesis

- Fusion confirmed on CT scans at 3 months post-surgery
- Weight-bearing at 6 weeks in CAM boot
- At 18 months follow-up, patient had no residual pain or other symptoms



Technique for Use of Trabecular Metal Spacers in Tibiototalcaneal Arthrodesis With Large Bony Defects.

Surgeon Author(s): Chris Kreulen, MD; Eric Giza, MD (UC Davis)

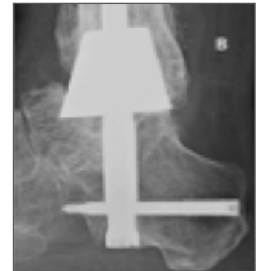Reference: *Foot & Ankle International*, 2017 Jan; 38 (1): 96-106.

"2 types of compression from the intramedullary TTC nail help stabilize this construct to ensure favorable outcomes."

Study Type: Case Series

No. of Patients: 6

- First report describing use of the DynaNail with Trabecular Metal spacers for TTCA to treat large bony defects
- 100% fusion in all 6 patients (2 with failed TARs and 2 with Charcot neuropathy)
- Average fusion time: 8 weeks
- No reported complications



Measurement of Nitinol Recovery Distance Using Pseudoelastic Intramedullary Nail in Tibiototalcaneal Arthrodesis.

Surgeon Author(s): Chris Gross, MD, Sam Adams, MD, Selene Parekh, MD, Beau Kildow, MD (Duke University)

Reference: *Foot & Ankle Specialist*, 2016 Dec; 9 (6): 494-499.

"The movement of the nitinol element suggests continuous compression at the arthrodesis site."

Study Type: Retrospective Case Series

No. of Patients: 15 (60% revisions, 27% smokers, 27% diabetics)

- First study to describe method for measuring the recovery distance of the DynaNail Compressive Element on radiographs
- Average follow-up time: 195 days
- Compressive Element recovered an average of 5.58 mm
- 86% of total recovered distance occurred within the first 40 days

